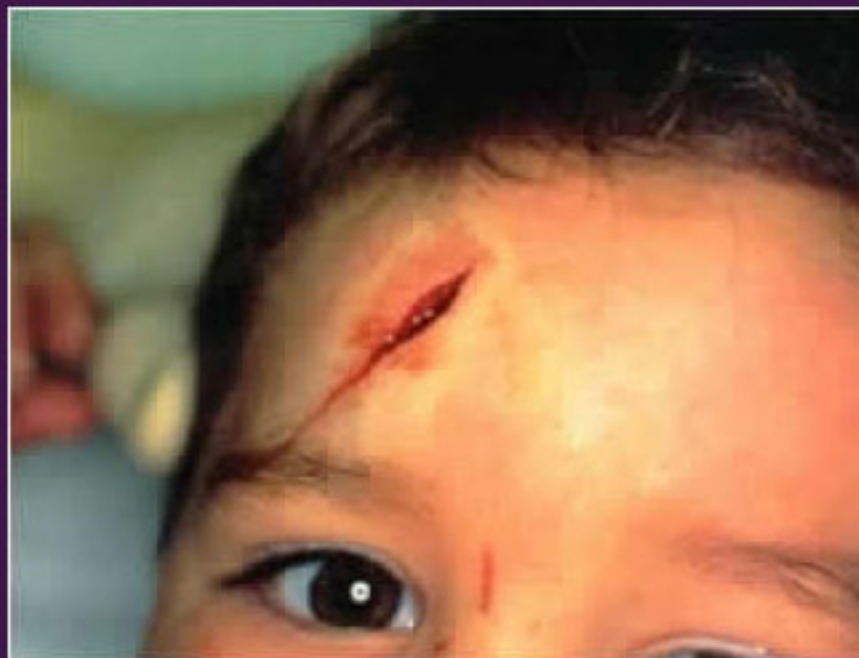

Introduction

In recent years, tissue adhesives have been used more and more often to repair simple lacerations.

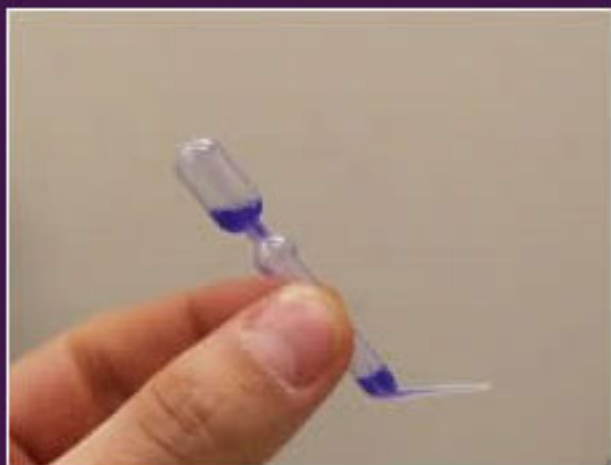
They are especially useful in pediatrics where we place a premium on the speed with which the laceration can be repaired while at the same time minimizing the associated pain.



Objectives

At end of this tutorial the clinician should be able to:

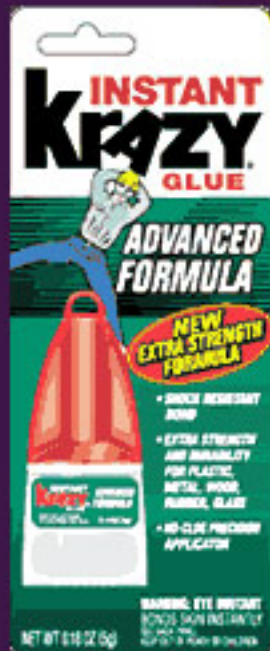- list the indications and contraindications for the use of tissue adhesives.
- describe the proper tissue adhesive technique.
- list possible complications.



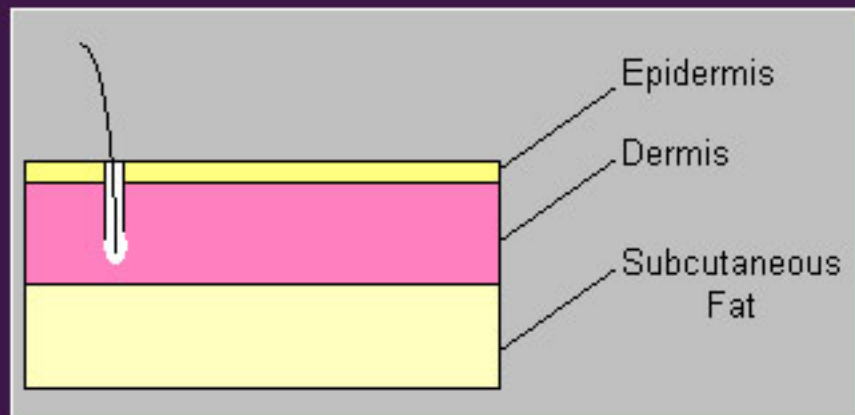
GluStitch® is similar to the various "Krazy Glues" available in hardware stores, however the wound closure material is made under GMP conditions and is purified for medical use. Within the vial it is liquid, however once exposed to moisture (hydroxyl ions), polymerization begins, and a bond is formed.

In most everyday situations where glues are used, two surfaces are bonded together by placing glue between them.

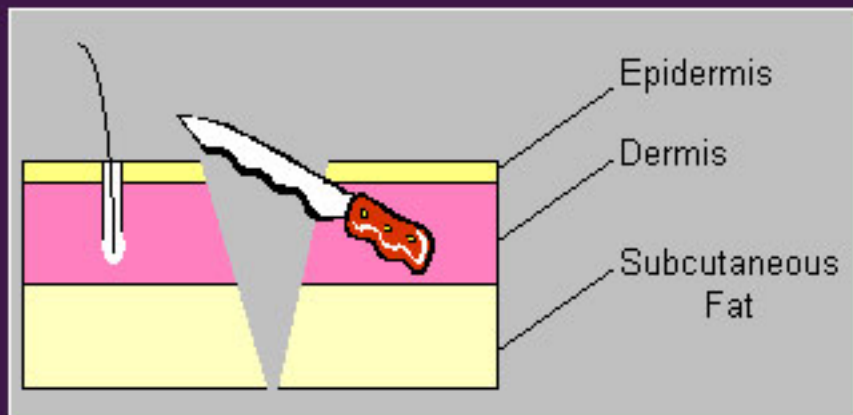
This is not how wound repair is accomplished.



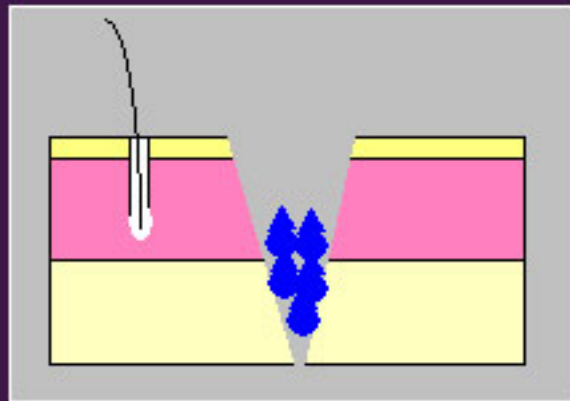
Consider this schematic of the skin.



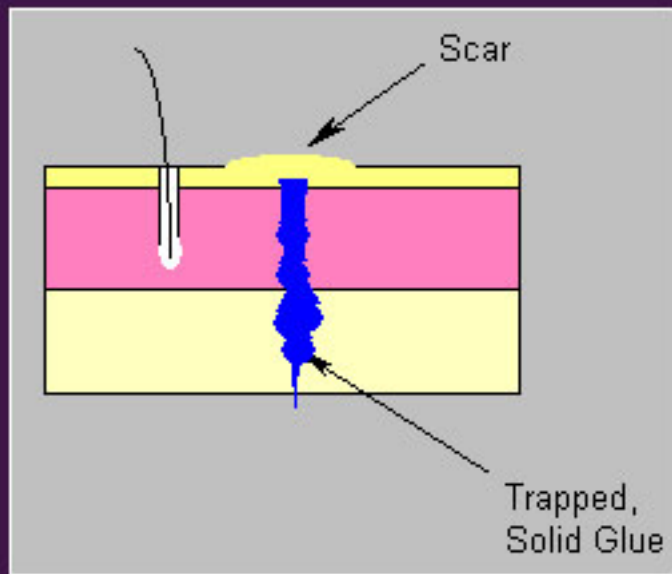
If we model a laceration, it is possible to show how **Glustitch®** is best used.



This diagram shows the **“incorrect way”** of attempting laceration repair. GluStitch® must **not** be placed in the laceration, and every effort must be made to prevent introduction of the material into the wound.

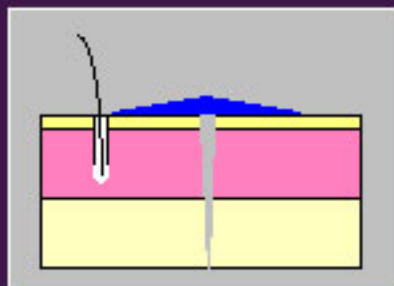
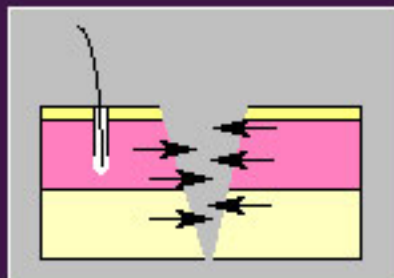


If we attempt to repair the laceration by putting the glue in the laceration, all we've succeeded in doing is creating a sub- or intra- cutaneous foreign body which impairs wound healing, and can result in serious complications.



Instead we do the following:

1. Bring the wound edges together.
2. Apply a thin layer of glue over and along the apposed wound edges.
3. Reinforce the repair with at least one, and preferably several coats of glue.



Which of the following should not be sutured?

- a) A laceration contaminated with farm soil.
- b) A human bite on the forearm.
- c) A wound that is 18 hours old.
- d) A wound under tension.

Which of the following should not be sutured?

The correct answers are:

- a) A laceration contaminated with farm soil.
- b) A human bite on the forearm.
- c) A wound that is 18 hours old.
- d) A wound under tension.

Which of the following are
contraindication to using of
Glustitch® for laceration repair?

- a) A laceration greater than 5 cm in length.
- b) A facial laceration.
- c) An animal bite.
- d) Wound is greater than 6 hours old.

Which of the following are
contraindication to using of
Glustitch® for laceration repair?

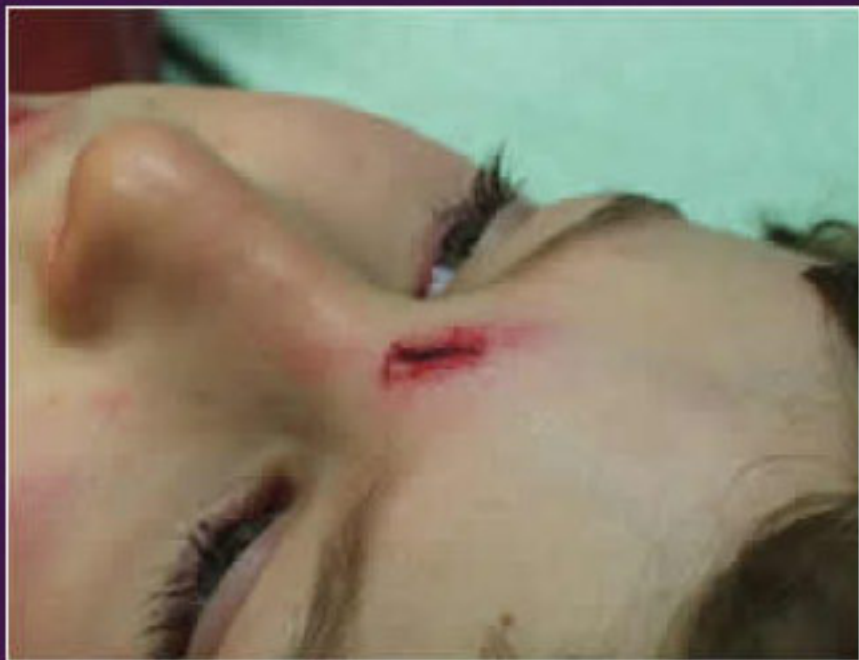The correct answer is:

- a) A laceration greater than 5 cm in length.
- b) A facial laceration.
- c) An animal bite.
- d) Wound is greater than 6 hours old.

The following are contraindications to using **GluStitch®** for wound repair.

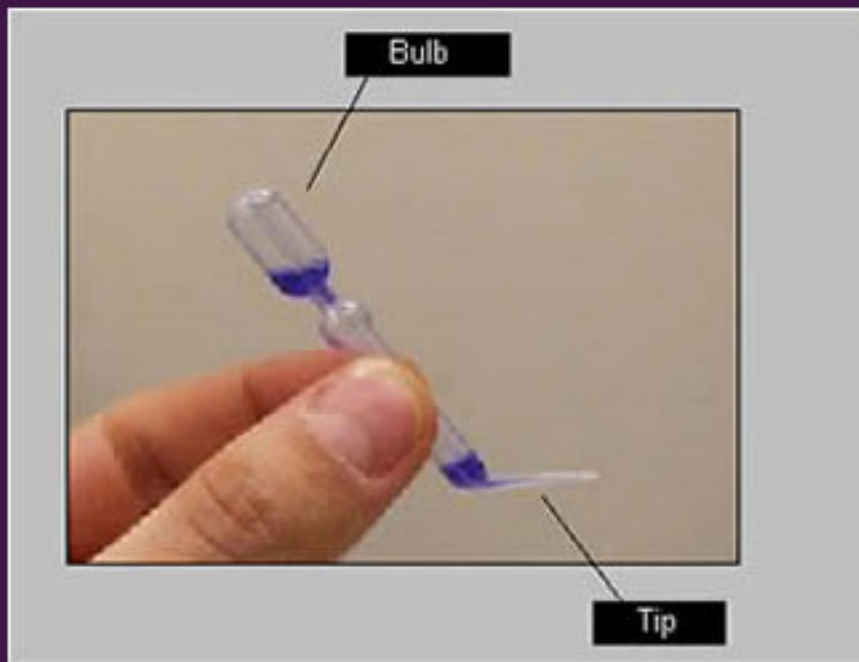
- 1) Laceration > 5 cm in length.
- 2) Gaping more than 0.5cm.
- 3) Skin under tension.

This young man fell and struck his face on the floor sustaining a laceration on the bridge of his nose.



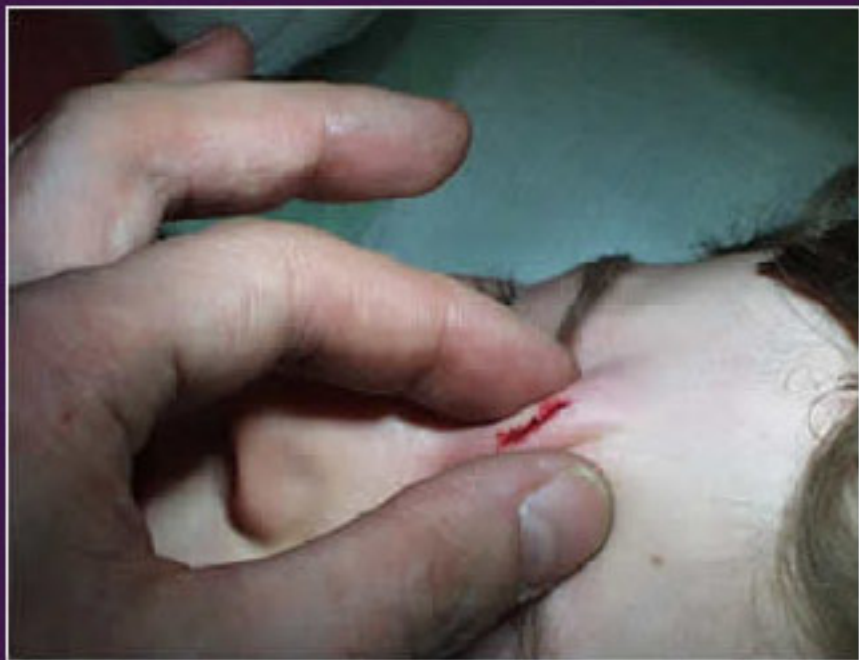Repair the wound for closure by cleaning with sterile solution and ensuring that hemostasis is achieved.

You should familiarize yourself with the **GluStitch®** delivery system to ensure you have total control over the adhesive. To begin, hold the tip upright, and clip the end with scissors. Position the patient to ensure that the wound is as level as possible.



The most important part of the technique is proper apposition of the wound edges.

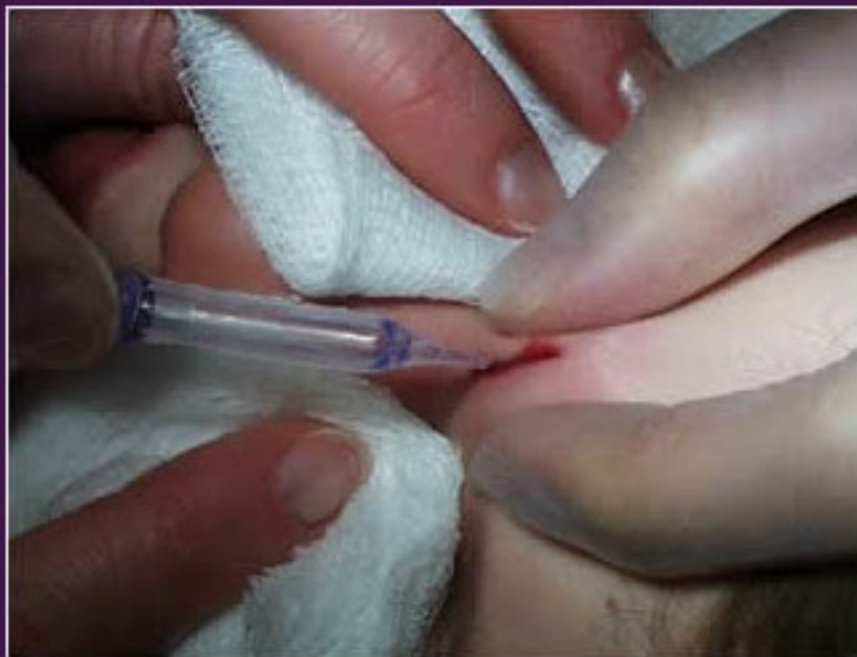This is shown here (in a non-sterile fashion). The adjoining tissues are bunched up between the fingers so that the actual wound edges are tightly apposed and free of tension.



Once the wound edges are nicely apposed, the glue should be applied and spread thinly using the application tip like a hockey stick.

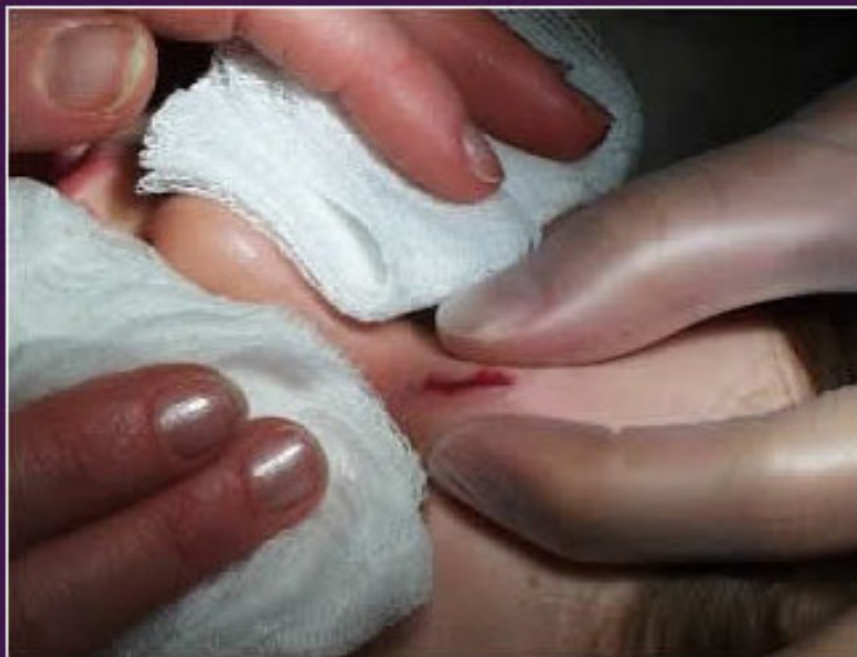Roll your mouse over the image to highlight the thin film of glue.

Always take precautions so that no glue drips into the child's eyes.



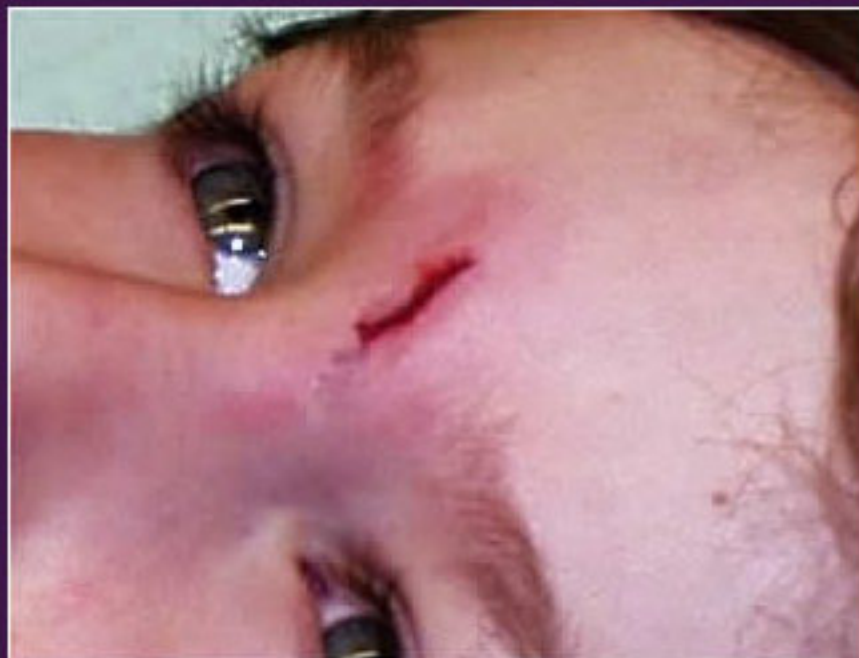After the glue is applied, the edges must be held in perfect apposition for 30 seconds until the glue has dried (and polymerized). Until then, the repair has no tensile strength.

Much of the final quality of the result depends not on your "surgical" skill but rather on your ability to keep a 2 year old still for 30 seconds !!

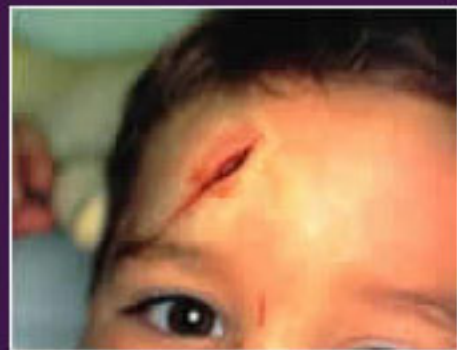

Here's the final result with the wound edges nicely apposed.

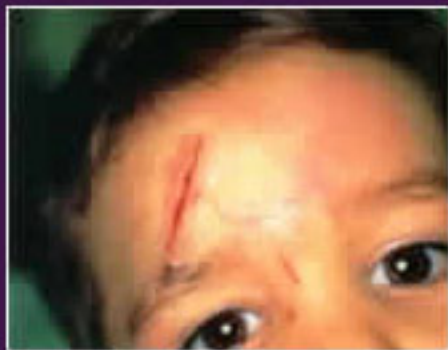This repair was relatively easy since the wound edges naturally stayed together.



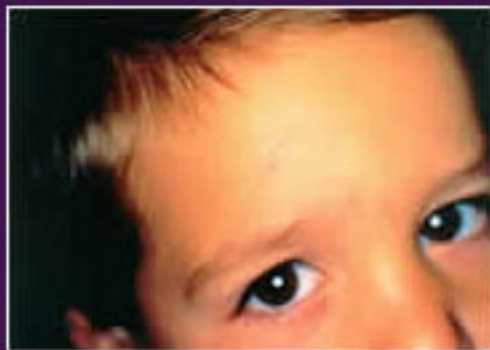Below are pictures showing the injury, glued wound, and three month results. The outcome was excellent using **GluStitch®**.



Injury

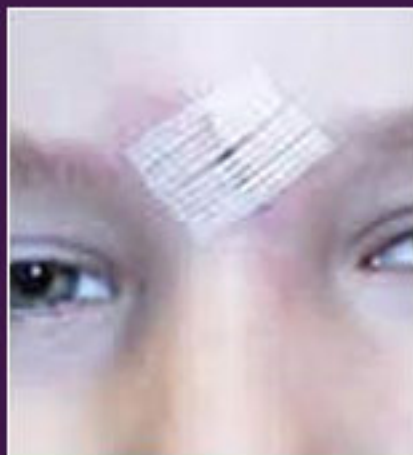

After Glue



3 Months Later

The final step is to lay tape strips over the DRIED glue to reinforce the repair.



Here are some of the possible complications associated with the use of **GluStitch®**

- 1) Gluing the operator to the patient !!!
- 2) Allergy.
- 3) Infection.
- 4) Wound dehiscence.

*GluStitch® has been on the market for more than 15 years with hundreds of thousands of applications. There have been no allergic or sensitive reactions reported. Infections, when they occur are rare, and are likely a result of poor wound preparation and not the glue, since GluStitch® has antibacterial properties.

Aftercare Instructions:

- ◆ Keep the wound clean and dry.
- ◆ Apply a dressing and change it daily.
- ◆ Allow the tape strips and adhesive to fall off naturally, usually in about five days.
- ◆ If you see infection or wound edge separation when changing the dressing, contact a physician immediately.
- ◆ When out in the sun, ensure that sunscreen is applied liberally to avoid pigment changes in the scar.

Remember these important points:

- ◆ Wounds longer than 5 cm. and wider than 0.5 cm. should not be glued.
- ◆ Do not introduce glue into the wound. It must be applied on top and along the surface of the apposed and slightly everted wound edges
- ◆ Apply several coats, and reinforce the repaired wound with tape strips.
- ◆ Explain the aftercare recommendations.

End of Tutorial